Imaging Guided Interventions: Focus on Architectural Distortion

Lilian Wang, MD
Assistant Professor of Radiology
Northwestern Medicine

Northwestern Medicine
FEINBERG SCHOOL OF MEDICINE

Overview

- Definition
- Etiologies
- Diagnostic evaluation
- Methods for tissue sampling
- Radiology pathology concordanc

BI-RADS Definition: Mammography

- Thin straight lines or spiculation radiating from a point

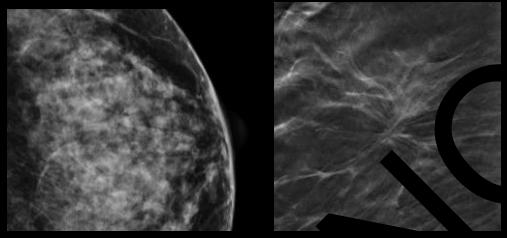

BI-RADS Definition: Mammography

- Fo traction, distortion, or straightening at the anterior or posterior edge of the parenchyma

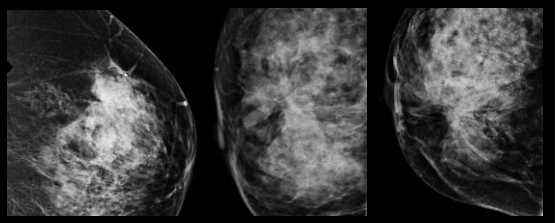

BI-RADS Definition: Mammography

- May be associated with asymmetry or calcifications
- Can also be an associated feature of a mass

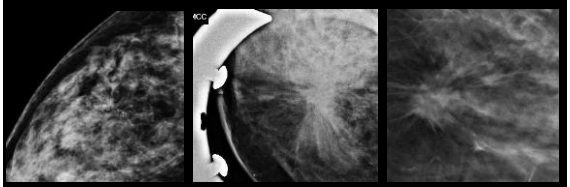

AD = "Black star"

White star

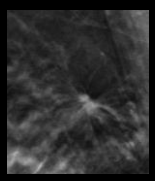

Black star

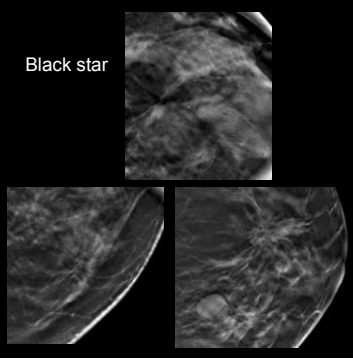

DO NOT COPY

(C) 2019 Lilian Wang, MD.

BI-RADS Definition: Ultrasound

- Listed as associated feature
- Compression of the tissue around the mass
- Obliteration of the tissue planes by an infiltrating lesion
- Straightening or thickening of Cooper's ligaments
- Aberrations of ductal pattern

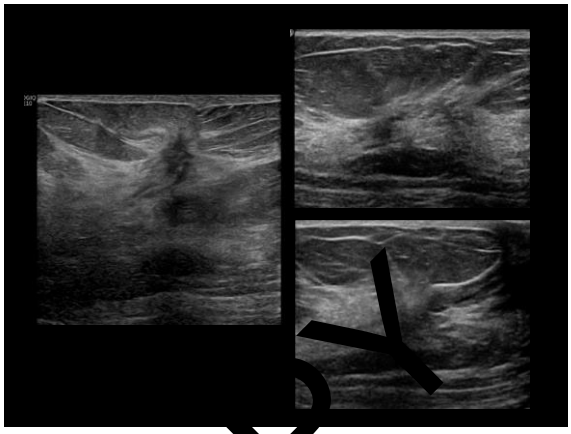

BI-RADS Definition: MRI

- Associated feature
- Used in conjunction with another finding to indicate that the parenchyma is distorted or retracted adjacent to the finding

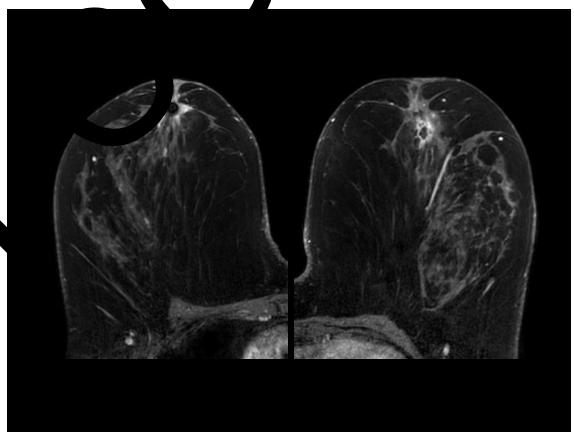

Architectural Distortion

- Third most common imaging appearance of breast cancer
- 12-45% of missed breast cancers on 2D screening mammography

Detection of AD

- Increased with DBT
  - Better visualized due to reduced superimposition
  - May reveal underlying mass with distortion

COPY

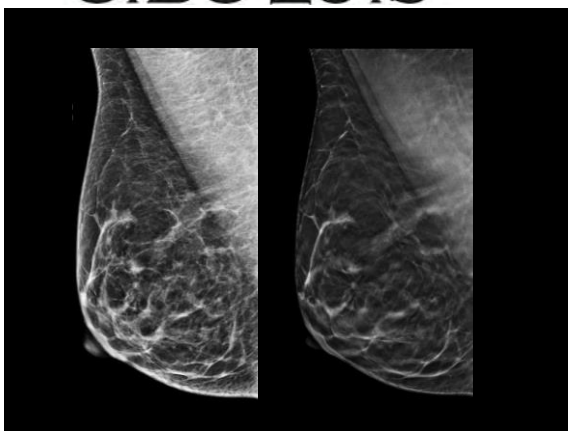

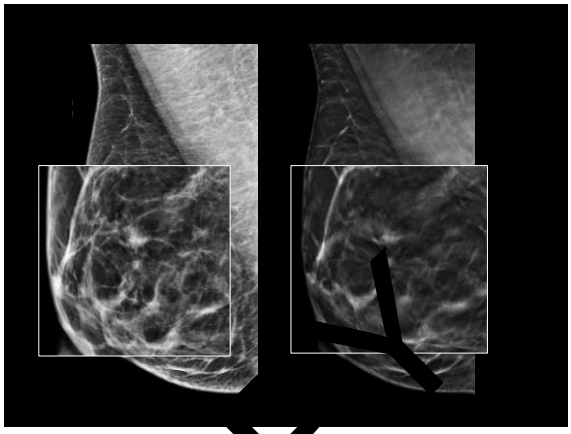

Study	Recall rate (% exams)		PPV3	
	DM	DBT	DM	DBT
Lourenco Radiology, 2015	0.6%	5.3%	100%	50%
Vijapura AJR, 2018	0.3%	0.6%	88%	68%
McDonald Radiology, 2017	6.1%	9.9%	-	
Bahl* AJR, 2017	0.07%	0.14%	73.6%	[illegible]%
Partyka AJR, 2014	-	0.5%	-	44%

*mammogram exams (diagnostic and screening)

[illegible] there really AD?

- [illegible]owest levels of interobserver agreement
- Agreement in mammographic interpretation was 43% for AD vs 100% for masses[1]
- Agreement among 10 experienced academic breast radiologists for AD fair (k=0.67)[2]
- Significantly lower sensitivity for AD vs. non-AD[3]

[1]Onega T, Smith M, Miglioretti DL, et al. J Am Coll Radiol 2012; 9:788–794.
[2]Lee AY, Wisner DJ, Aminolotama-Shakeri S, et al. Acad Radiol. 2017 Jan;24(1):60-66.
[3]Suleiman WI, McEntee MF2, Lewis SJ. Clin Radiol. 2016 Jan;71(1):e35-40.

Architectural Distortion?

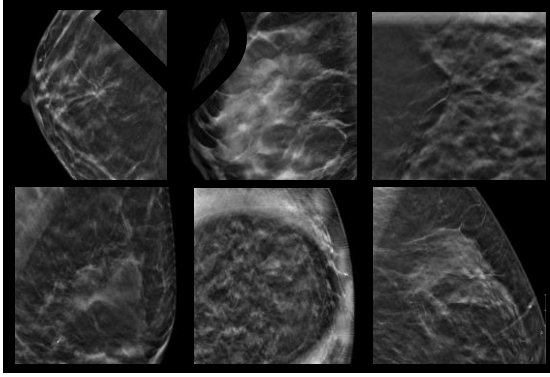

Architectural Distortion?

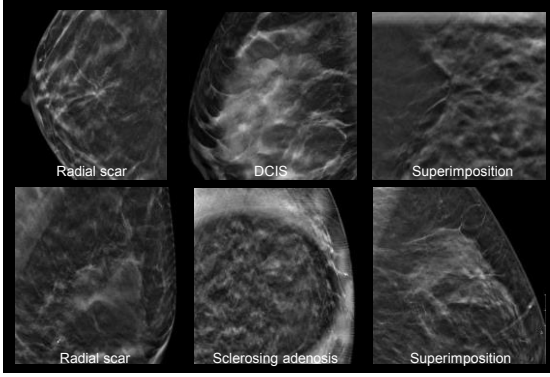

COPY

Interobserver Variability

- 3 readers agreed on presence of AD in only 26 of 51 recalls for AD.[1]
- 181 AD (122 2D, 59 DBT), 3 readers:[2]
  - Fair agreement, κ = 0.29-0.37
  - Moderate to substantial agreement for level of suspicion
    - κ = 0.51-0.64, 79.3-84.4% agreement
    - κ = 0.32-0.36 for 2D-detected lesions
    - κ = 0.14-0.36 for DBT-detected lesions

[1]Partyka et al., Detection of mammographically occult architectural distortion on digital breast tomosynthesis screening: initial clinical experience. AJR 2014.
[2]Alshafeiy et al. Outcome of architectural distortion detected only at breast tomosynthesis versus 2D mammography. Radiology 2018.

Increased Agreement with DBT

- 59 AD patients and 59 controls, 4 readers
- DBT vs 2D:
  - decreased interobserver variability
  - increased reader confidence
  - improved sensitivity

Dibble et al., Comparison of digital mammography and di[illegible]st tomosynthesis[illegible] detection of architectural distortion. Eur Radiol 2018.

Etiologies

- Malignancy
- Radial scars and complex sclerosing lesions
- Post-procedural scars from surgery, biopsy, reduction mammoplasty
- Fibrosis
- Fat necrosis
- Sclerosing adenosis
- Fibromatosis with fibroblastic and my[illegible]fibro[illegible]stic proliferation

Corre[illegible]ate with Clinical History

- In a[illegible]nce of history of trauma or surgery, AD is considered suspicious → tissue diagnosis

Post-surgical AD

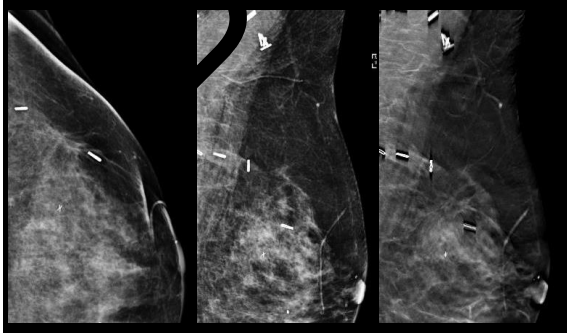

Diagnostic Evaluation of AD

- If presumed post-surgical, confirm with scar marker

(C) 2019 Lilian Wang, MD.

Post-surgical AD?

65-year-old submits outside imaging for review.

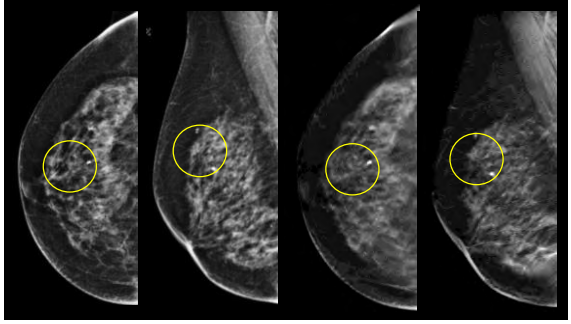

Post-surgical AD?

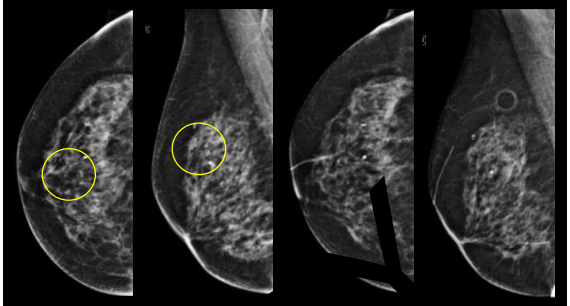

AD confirmed to be post-surgical after placement of linear radiopaque scar marker.

Diagnostic Evaluation of AD

- If not post-surgical:
  - Lateral and spot compression views
  - Beware of potential for cancer to "spot away"
  - If one view only, utilize the scroll bar or adjacent landmarks for lesion localization

Two areas of AD left UOQ on screening mammography

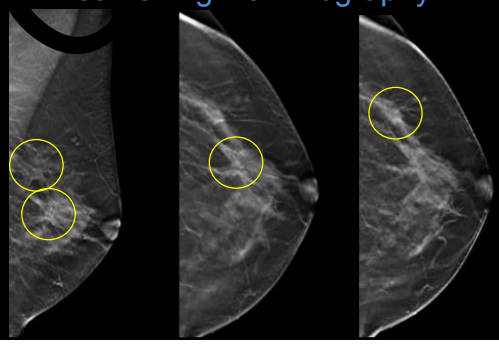

Diagnostic lateral and spot compression views

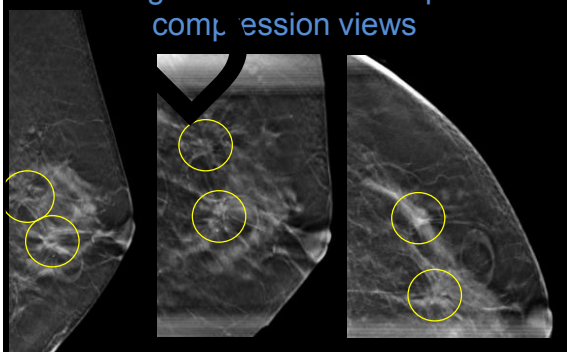

Two persistent areas of architectural distortion.

Ultrasound

- Perform for mammographically suspicious AD to allow for US biopsy
- PPV for malignancy greater with US correlate
- If US correlate is vague, use skin marker (BB) to confirm correlation

(C) 2019 Lilian Wang, MD.

US correlates

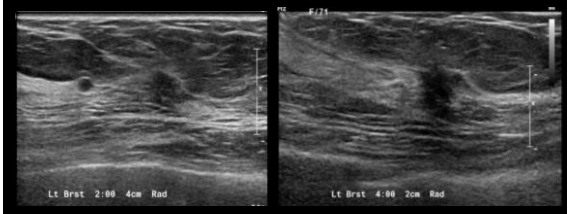

Invasive mammary carcinoma, grade 1 and DCIS, grades 1 and 2

Invasive ductal carcinoma with tubular features, grade 1 and DCIS, grades 1 and 2

40-year-old recalled from baseline screening mammography

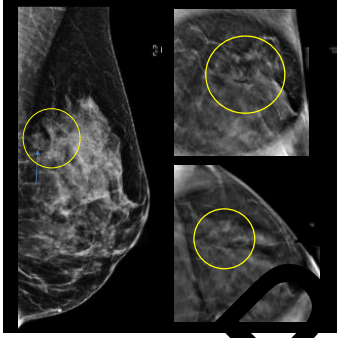

Use adjacent landmarks to identify subtle US correlate.

Biopsy revealed radial scar.

40-year-old recalled from baseline screening mammography

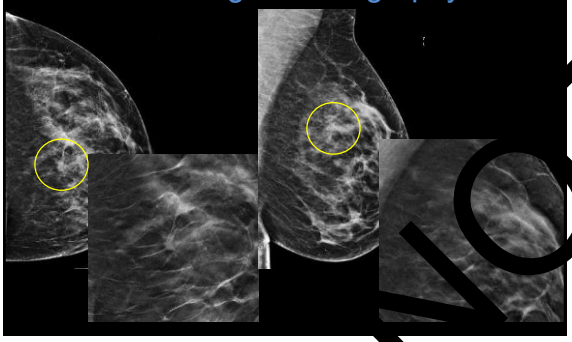

Diagnostic Evaluation

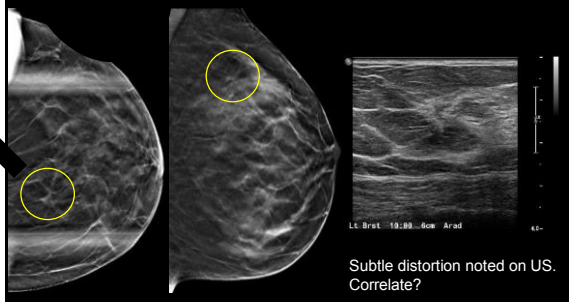

Subtle distortion noted on US. Correlate?

MG-US correlation with BB

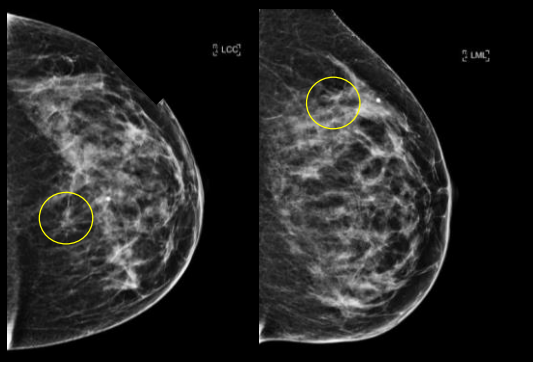

Post-biopsy clip confirmation

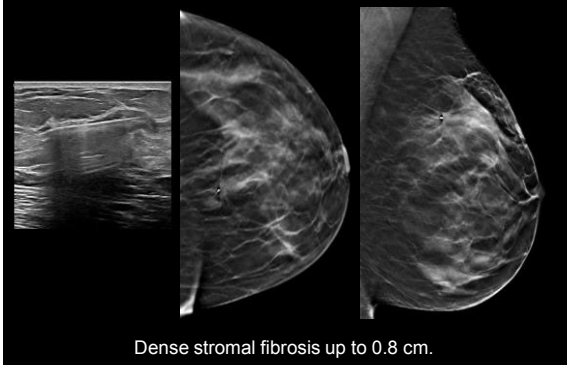

Dense stromal fibrosis up to 0.8 cm.

DO NOT COPY

62-year-old woman annual mammography

Post-biopsy clip correlation

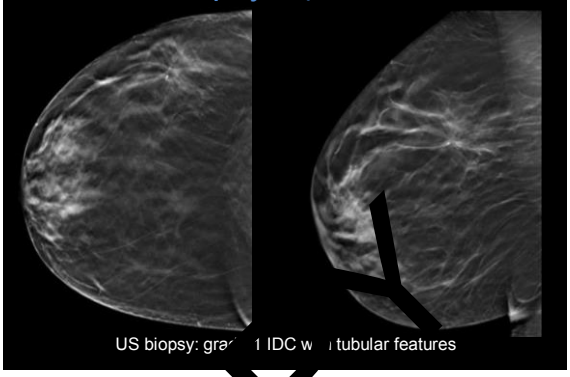

US biopsy: gra[illegible] IDC w[illegible] tubular features

47-year-old recalled from screening mammography

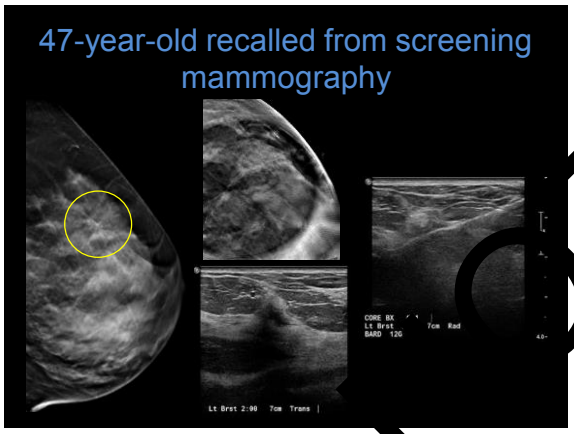

US biopsy clip does not correlate

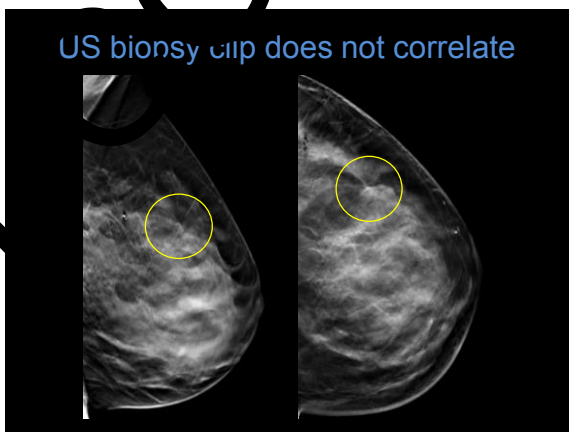

Stereotactic biopsy was performed

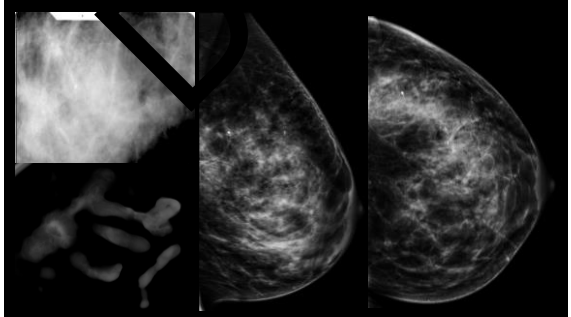

US biopsy: Benign. Stereotactic biopsy: radial scar.

Tissue Sampling

- If US correlate, US biopsy can be performed with confirmation of clip on post-biopsy MG
- AD without US correlate has PPV >2% → therefore tissue sampling warranted

COPY

Study	% cancer DBT-only AD
Partyka AJR, 2014	21% (4/19)
Freer Radiology, 2015	47% (17/36)
Ray Breast J, 2015	36% (5/14)
Patel AJR, 2018	26% (9/34)
Alshafeiy Radiology, 2018	10% (6/59)
Pujara Clin Imaging, 2019	9% (1/11)

Tissue Sampling

- If no US correlate:
  - DBT-guided biopsy
  - Stereotactic biopsy utilizing landmarks
  - Excisional biopsy after DBT needle localization
  - MRI for problem solving
  - CESM for problem solving

61-year-old recalled from screening mammography for AD in the outer right breast and upper outer left breast.

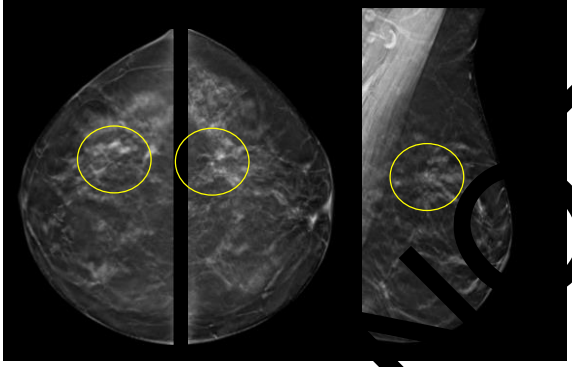

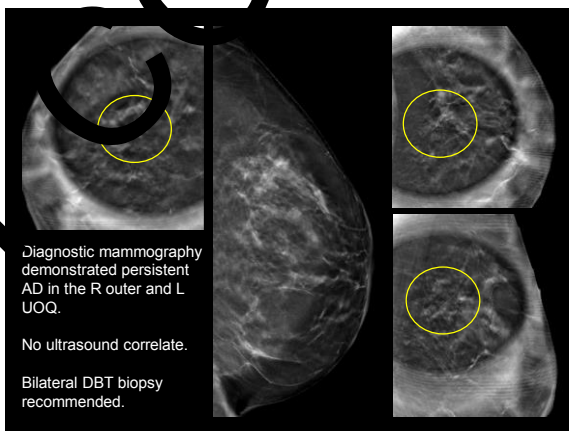

Diagnostic mammography demonstrated persistent AD in the R outer and L UOQ.

No ultrasound correlate.

Bilateral DBT biopsy recommended.

Right DBT biopsy

Left DBT biopsy

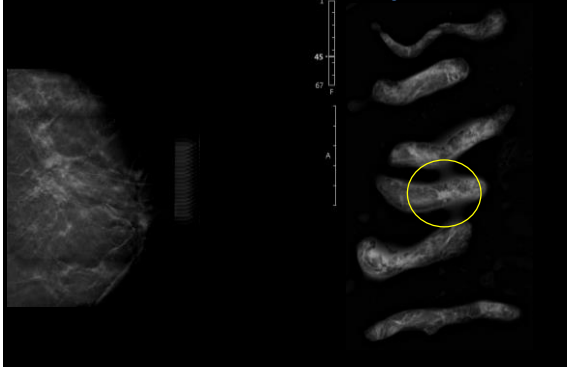

Do Not Copy

Post-biopsy clip confirmation

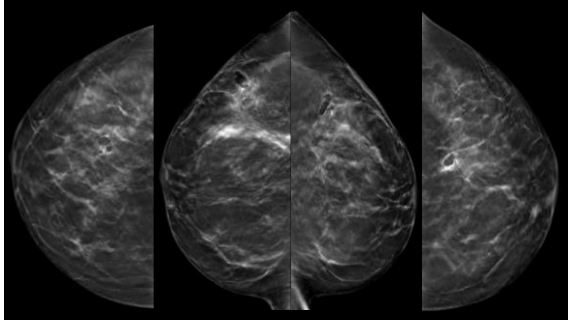

Bilateral radial scars

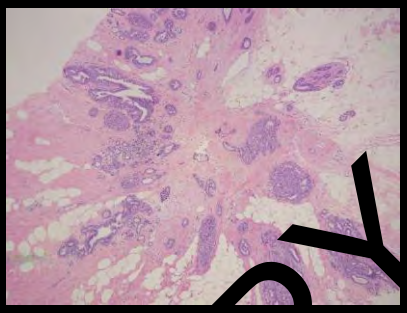

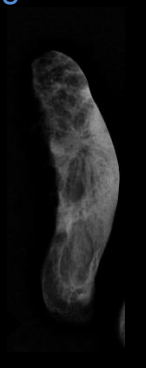

Radial scar

- Benign lesion characterized by a central fibroelastic core surrounded by radiating ducts and lobules
- Referred to as complex sclerosing lesions if >1 cm in size
- 14-26% of patients at autopsy[1]
- 0.9 per 1000 prevalence screening exams[2]
- 0.8-1.8% of image-guided biopsies[3,4]

[1]Wellings et al. Subgross pathologic features and incidence of radial scars in the breast. Human Pathol
[2]Tabar and Dean. Teaching atlas of mammography, 3rd ed. 2001.
[3]Kim et al. Isolated radial scar diagnosis by core needle biopsy is surgical excision necessary? Springerpla
[4]Linda et al. Radial scars without atypia diagnosed at imaging-guided needle biopsy: how often is associated ... found at subseq... ...n, and do mammography and sonography predict which lesions are malignant? AJR 2010.

Radial scars and breast cancer

- ... pre... alignant lesions
- Proliferative lesions that often coexist with other proliferative lesions, including atypia, that may contribute to upgrade
- Coexist with cancers at a higher frequency than chance alone
- Likely does not impart increased risk of future breast cancer,[1,2] although literature mixed[3]

[1]Sanders et al. Interdependence of radial scar and proliferative disease with respect to invasive breast carcinoma risk in patients with benign breast biopsies. Cancer 2006.
[2]Berg et al. Breast cancer risk in women with radial scars in benign biopsies. Breast Cancer Res Treat 2008
[3]Jacobs et al. Radial scars in benign breast-biopsy specimens and the risk of breast cancer. New Engl J Med 1999.

Upgrade of Radial Scars

- Upgrade rate 0-... % (usually to DCIS):
  - sampling method
  - biopsy device and gauge
  - number of samples
  - targeted abnormality
  - associated atypia
  - criteria for excision (selection bias)
  - imaging-pathology concordance/discordance

Cohen and Newell. Radial scars of the breast encountered at core biopsy: Review of Histologic, Imaging, and Management Considerations. AJR 2017;209:1168-1177.

Upgrade of Radial Scars

- Larger-gauge vacuum-assisted devices and more cores → significantly lower upgrade rates[1]
  - For RS without atypia:
    - 5% 14G CNB
    - 2% 8-16G CNB
    - 1% VAB
- Cancers often identified in a peripheral location within radial scars → potential undersampling at CNB site[2]

[1]Farshid and Buckley. Meta-analysis of upgrade rates in 3163 radial scars excised after needle core biopsy diagnosis. Breast Cancer Res Treat 2019; 174(1):165–177.
[2]Douglas-Jones et al. Radial scar lesions of the breast diagnosed by needle core biopsy: analysis of cases containing occult malignancy. J Clin Pathol 2007;60:295-298.

COPY

Management of Radial Scars

- Traditionally surgical excision due to risk of associated malignancy based on film-screen, FFDM and/or US findings
- Review: upgrade rate pure RS – 3.4% (0-16%)[1]

[1]Chou et al. Radial scar on image-guided breast biopsy: is surgical excision necessary? Breast Cancer Research and Treatment 2018.

DBT and Radial Scars

- DBT → increased AD → increased RS
  - 15.3% of HRL in DBT group vs. 9.7% in DM group[1]
  - 33.2% of AD in DBT group vs. 11.6% in DM group[2]
  - 0.13% of exams in DBT group vs 0.04% in DM group[3]
  - Associated malignancy rate 2-29%[1, 4-5]

[1]Lamb et al. Pathologic upgrade rates of high-risk breast lesions on digital[2] ...nsional vs tomosynthesis ...ography. J Am Coll Surg 2018.
[2]Bahl et al. Pathologic Outcomes of Architectural Distortion on Digital ...ynthesis Mammography. ...2017.
[3]Phantana-Angkool et al. Rate of radial scars by core biopsy and ...ng to ma... ...y or high-risk lesions befo... ...fter introduction of digital breast tomosynthesis. Breast Cancer Res Treat. 2019 Jan;173(...
[4]Martaindale et al. Imaging Follow-up Versus Surgical Excisi... ...adial Scars Iden... ...on Tomosynthesis-Guided Core Needle Biopsy. Academic Radiology 2019.
[5]Freer et al. Preoperative tomosynthesis-guided needle l... ...on of mammograp... ...y and sonographically occult breast lesions. Radiology 2015.

Radial scars without atypia

- Low upgrade rates reported:
  - 0% (0/100)[1]
  - 0% (0/39, 0/13, 0/15)[2-4*]
  - 2% (2/91)[5]
  - 4% (5/128 – AD 3/5 cases)[6]

[1]DBT era
[2]Kalife et al. Clinical and Radiologic Follow-up Study for Biopsy Diagnosis of Radial Scar/Radial Sclerosing Lesion witho... ...atypia. Breast ...
[3]Martaindale et al. Imaging Follow-up Versus Surgical Excision for Radial Scars Identified on Tomosynthesis-Guided Core N... ...iopsy. Academic Radiology 2019.
[4]Pujara et al. Architectural distortion in the era of digital breast tomosynthesis: outcomes and ... → Clin In... ...2019.
[5]Alshafeiy et al. Outcome of Architectural Distortion Detected Only at Breast Tomosynthesis ve... ...) Mamm...
[6]Chou et al. Radial scar on image-guided breast biopsy: is surgical excision necessary? Breast Ca... ...esearch and Treat...
[6]Brenner et al. Percutaneous Core Needle Biopsy of Radial Scars of the Breast: When Is Excision N... ...? AJR 2002.

MRI for Radial Scars

- ... high risk lesions, including 54 radial scars
  - NPV for radial scar = 97.6%
  - 1 FN: low-grade DCIS
  - Clinical and imaging follow-up with normal MR findings?

Linda et al. Nonsurgical management of high-risk lesions diagnosed at core needle biopsy: can malignancy be ruled out safely with breast MRI? AJR 2012.

Radial Scar Management: Controversial

- Excise all?
- Case by case analysis?
- Imaging and clinical follow-up?

Management Considerations

- Has target been sufficiently sampled?
  - Consider # cores and gauge, lesion size
  - Is clip in appropriate position?
- Is pathology concordant with imaging findings?
- Is radial scar incidental?
- Patient factors: current cancer or personal history of breast cancer, high risk factors

COPY

Potential Management Algorithm: Radial Scars

- <1 cm, concordant → imaging follow-up
- >1cm, concordant → consider excision or repeat sampling with large gauge vacuum-assisted device
- Incidental, concordant → imaging follow-up

Newell et al. Radial Scars of the Breast Encountered at Core Biopsy: Review of Histologic, Imaging, and Management Considerations. AJR 2017.

57-year-old woman recalled from screening mammography.

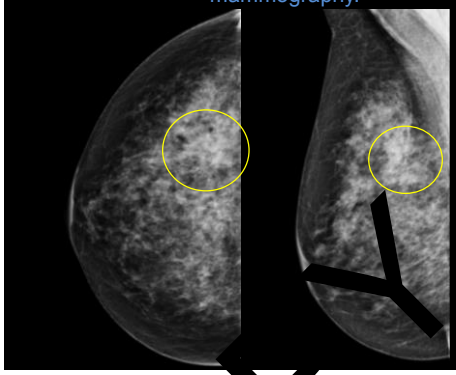

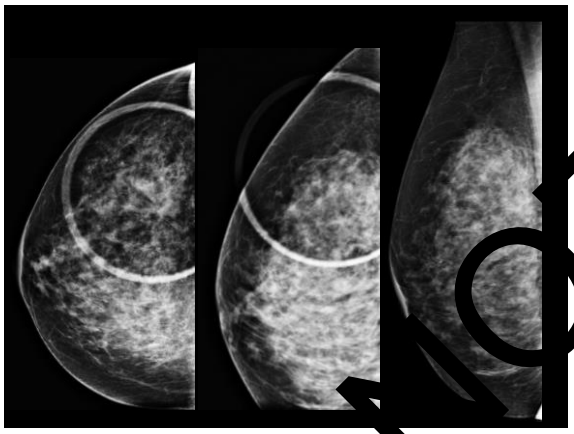

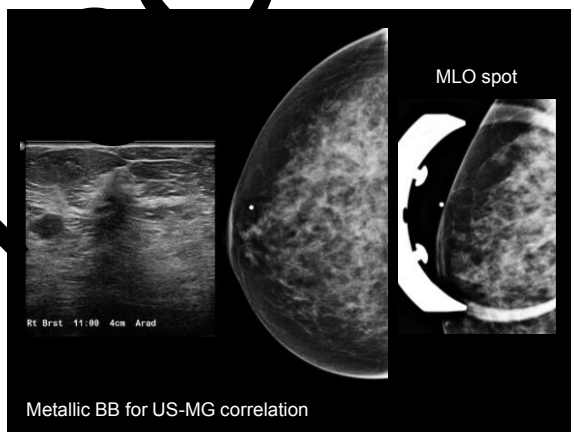

Metallic BB for US-MG correlation

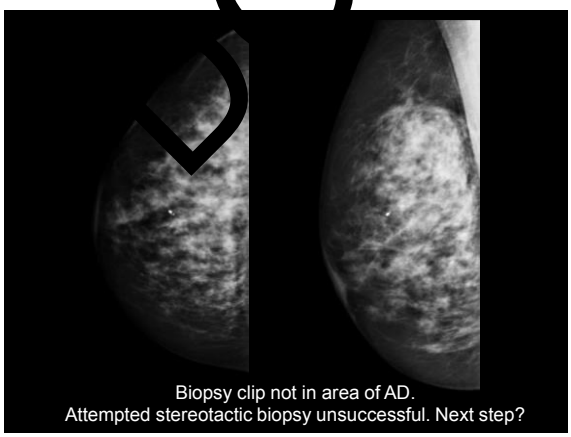

Biopsy clip not in area of AD.
Attempted stereotactic biopsy unsuccessful. Next step?

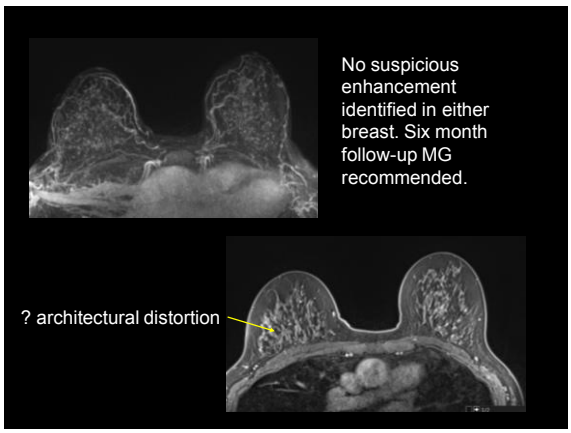

DO NOT COPY

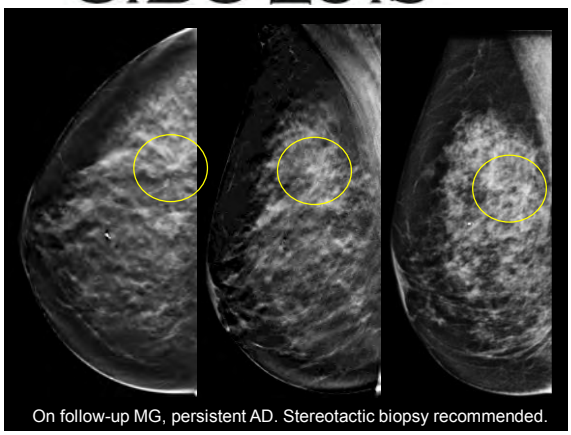

On follow-up MG, persistent AD. Stereotactic biopsy recommended.

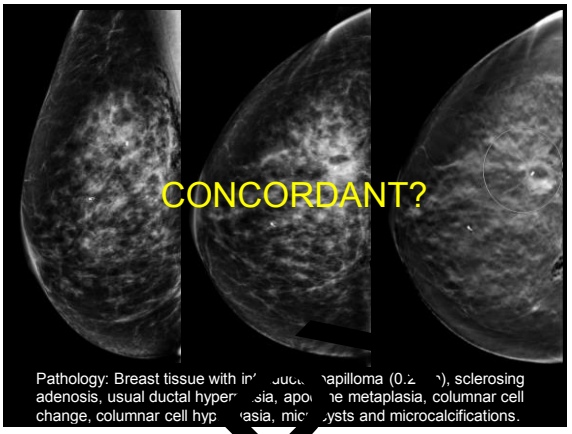

Pathology: Breast tissue with in[illegible] papilloma (0.[illegible]), sclerosing adenosis, usual ductal hyper[illegible]sia, apo[illegible]e metaplasia, columnar cell change, columnar cell hyp[illegible]asia, mic[illegible]ysts and microcalcifications.

After review of pathology and imaging at Radiology Pathology concordance conference, pathology was considered benign and concordant.

Six month mammographic follow-up was recomme[illegible]ed.

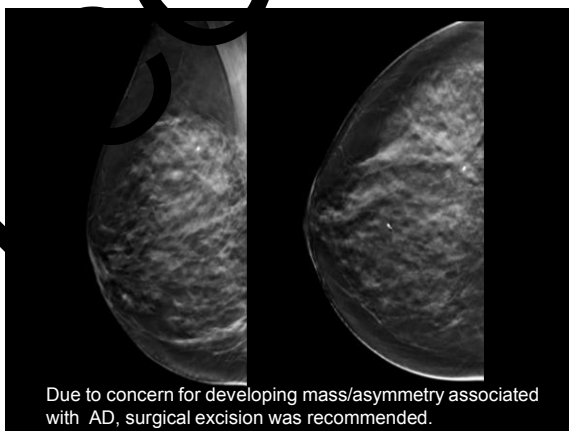

Due to concern for developing mass/asymmetry associated with AD, surgical excision was recommended.

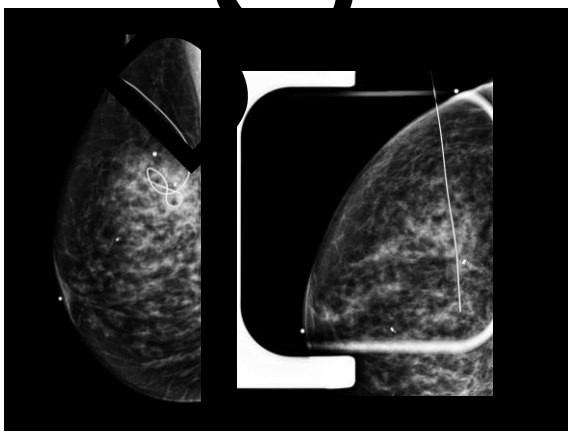

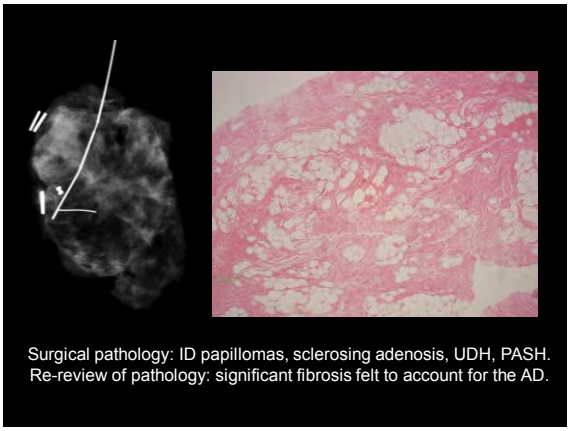

Surgical pathology: ID papillomas, sclerosing adenosis, UDH, PASH.
Re-review of pathology: significant fibrosis felt to account for the AD.

(C) 2019 Lilian Wang, MD.

60-year-old recalled from screening mammography.

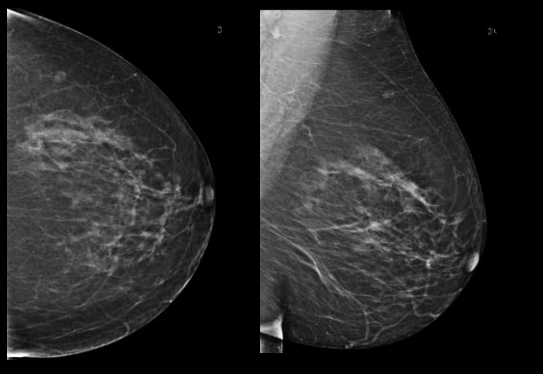

Diagnostic Mammogram

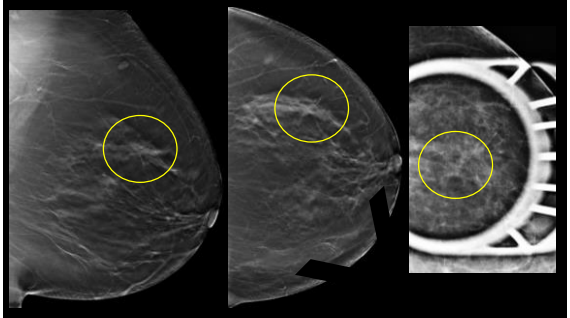

Persistent AD in the upper outer left breast. No ultrasound correlate. Stereotactic biopsy was recommended.

Post-biopsy mammogram after stereotactic biopsy

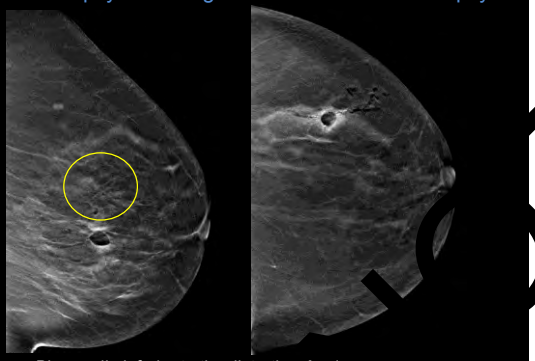

Biopsy clip inferior to the distortion. MR recommended.

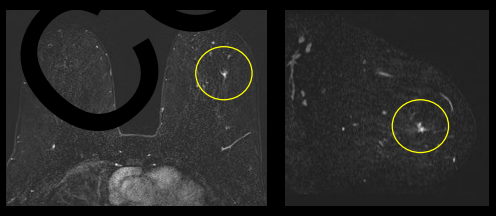

A 1.2 cm irregular enhancing mass was identified at 2:00 in the left breast corresponding to the area of distortion.

MR biopsy was performed.

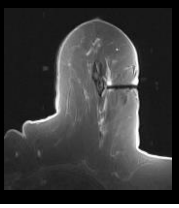

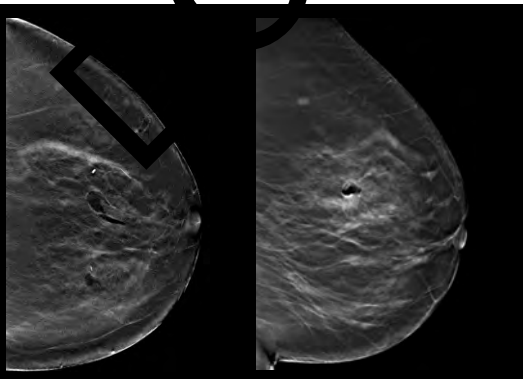

Pathology: Part of a radial scar (0.5 cm), ALH

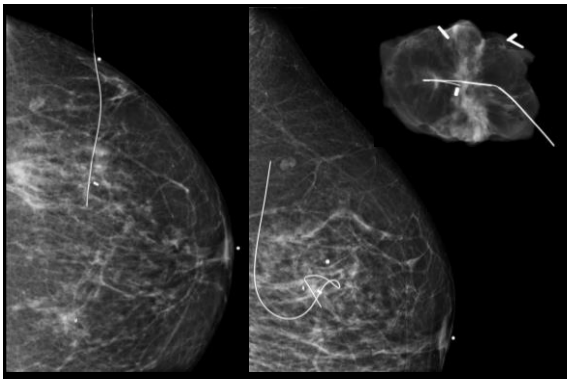

Surgical pathology: Radial scar

DO NOT COPY

MRI for Problem Solving

- Frequency should be low
  - 1.3-4% of MR exams[1-3]
  - 0.7-0.14% of Dx mammograms[2,3]

[1]Niell et al. Utility of Breast MRI for Further Evaluation of Equivocal Findings on Digital Breast Tomosynthesis. AJR 2018 211:5, 1171-1178.
[2]Moy et al. Is Breast MRI Helpful in the Evaluation of Inconclusive Mammographic Findings? AJR 2009;193:986-993.
[3]Giess et al. Clinical Utility of Breast MRI in the Diagnosis of Malignancy After Inconclusive or Equivocal Mammographic Diagnostic Evaluation. AJR 2017 208:6, 1378-1385.

Problem-Solving MRI

Study	No. of Equivocal Mammographic Lesions	Malignancies	False-negative MR Imaging	Incidental Findings	Malignant Incidental Lesions
Sardanelli et al (1)	19	5 (26.3%)	1 (20%)	Not reported	
Lee et al (2)	86	9 (10.5%)	0 (0%)	12*	1 (8.3%)
Moy et al (3)	115	6 (5.2%)	0 (0%)	18†	0 (0%)
Spick et al (4)	111	15 (13.5%)	0 (0%)	Not reported	
Oztekin and Kosar (21)	130	7 (5.4%)	0 (0%)	Not reported	
Brigham and Women's Hospital‡	294	40 (13.6%)	3 (7.5%)	44§	7 (17.1%)‖

- Malignant diagnosis in 5.2-26.3% of M I cases for equivocal findings on DM
- Few or no false negative exa

Table from Giess et al. Breast MR Imaging for Equivocal Mammog findings: Help or Hir ? Radiographics. 2016 Jul-Aug;36(4):943-56.

Problem-Solving MRI

- Moy: 12 AD, 7 one-view only[1]
  - Malignancy rate 8.3% (one-view AD)
  - Overall Sensitivity 100%, NPV 100%
- Spick: 57 AD[2]
  - TP 8, TN 44, FP 5, FN 0
  - Malignancy rate 14%
  - Sensitivity 100%, NPV 100%

[1]Moy et al. Is Breast MRI helpful in the evaluation of inconclusive mammographic findings? AJR 2 9(4):986-993.
[2]Spick et al Breast MRI used as a problem-solving tool reliably excludes malignancy. Eur Jnl Radio 94(1):61-64

Breast MRI after Equivocal Mammographic Diagnostic Evaluation

- 4 94 women undergoing problem-solving MRI
- Of 8 malignant AD:
  - 6 with MR correlate:
    - 2 one-view AD (ILC, IDC)
    - 4 two-view AD (IDLC, 2 DCIS, IDC)
  - 2 with no MR correlate:
    - 1 one-view AD (IDC)
    - 1 two-view AD (IDC)
- Overall FN 7.5% (3/40): 2AD, 1 asymmetry
- Overall Sensitivity 92.5%, NPV 97.8%

Giess et al. Clinical Utility of Breast MRI in the Diagnosis of Malignancy After Inconclusive or Equivocal Mammographic Diagnostic Evaluation. AJR Am J Roentgenol. 2017 Jun;208(6):1378-1385.

MR f Equiv cal DM/DBT Findings

- 67 equi cal D M/DBT findings
  - 9 (13%) e-view AD: 2 MRI findings, 0 cancer
  - 10 (15%) two-view AD: 4 MRI findings, 1 cancer
- Overall malignancy rate 7% (5/67)
- PPV 19%, NPV 98%

Niell et al. Utility of Breast MRI for Further Evaluation of Equivocal Findings on Digital Breast Tomosynthesis. AJR 2018 211:5, 1171-1178.

MRI for Equivocal DBT Findings

- 107 DBT-only lesions (79 AD, 28 asymmetries)
  - 50/79 AD had correlative MR finding
    - 14/50 (28%) invasive carcinoma
    - 36/50 (72%) benign
  - MR negative: no cancers at average follow-up of 32 months

Taskin et al. Review and management of breast lesions detected with breast tomosynthesis but not visible on mammography and ultrasonography. Acta Radiol 2017 Dec;58(12):1442-1447.

PROOF

56-year-old recalled from screening mammography.

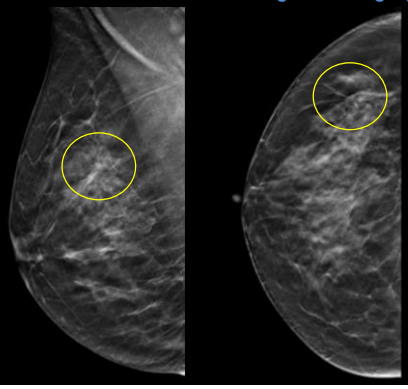

Diagnostic Mammogram

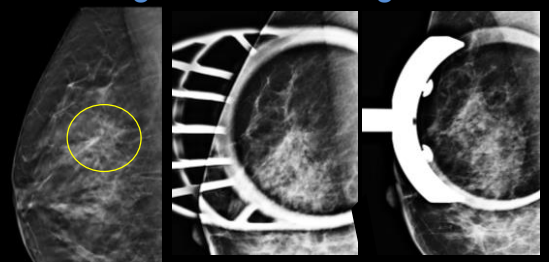

Persistent AD . . . erior breast.
No US correlate.

Ster .actic bi sy recommended.

Attempted stereotactic biopsy unsuccessful.

Breast MRI recommended for further evaluation.

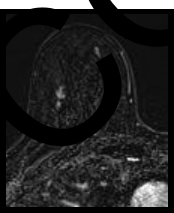

2.5 cm NME right UOQ which may correlate with AD. MR biopsy recommended.

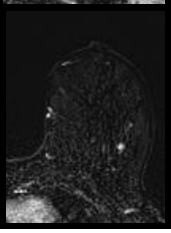

Incidental 0.7 cm enhancing mass left 3:00. MR biopsy recommended.

Post-biopsy Mammogram

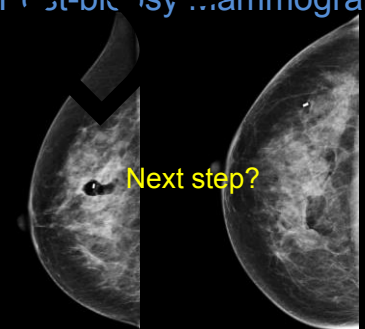

Next step?

Both MR biopsies benign.
R MR biopsy clip is anterior to the area of AD.

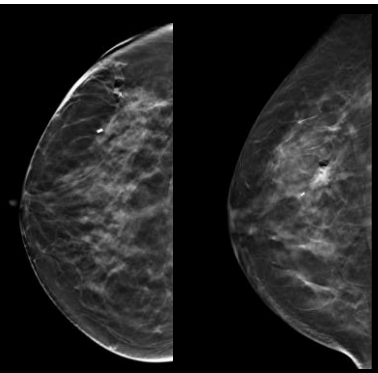

Re-attempted stereotactic biopsy yielded a radial scar.

Do not copy

72-year-old referred from OSH for MRI evaluation of AD L UOQ, no US correlate.

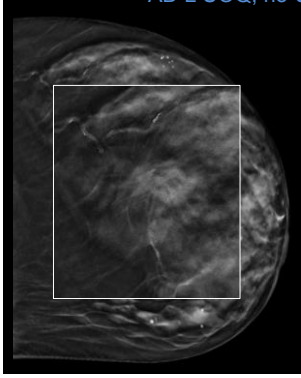

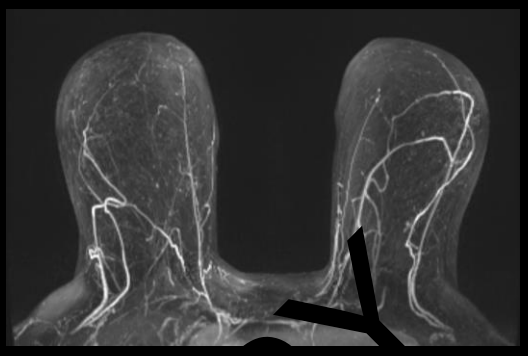

No suspicious enhancement on MRI.

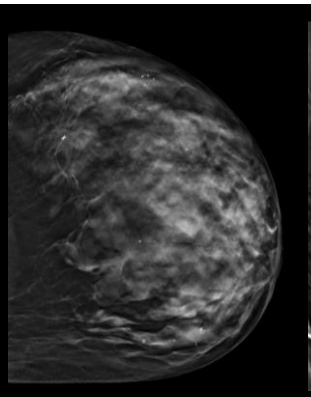

DBT biopsy = ADH, part of a complex sclerosing lesion.

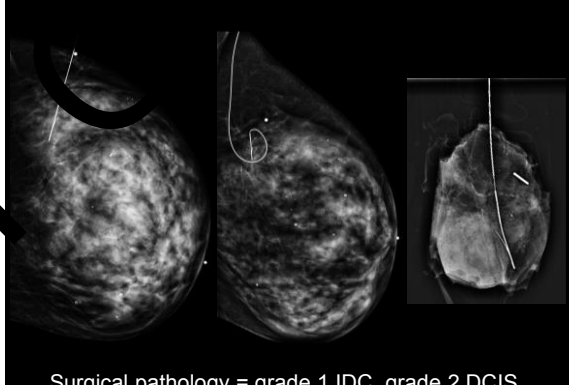

Surgical pathology = grade 1 IDC, grade 2 DCIS.

MRI for Problem Solving

- Can be used for equivocal mammographic lesions
- Negative or benign MR: ambiguous finding likely not clinically significant → can do f/u
- Positive MR finding: increases clinical suspicion and can guide tissue diagnosis
- Not appropriate for suspicious, two-view mammographic findings for which biopsy is recommended
  - NPV of MR not considered high enough to obviate tissue diagnosis

Diagnostic Algorithm

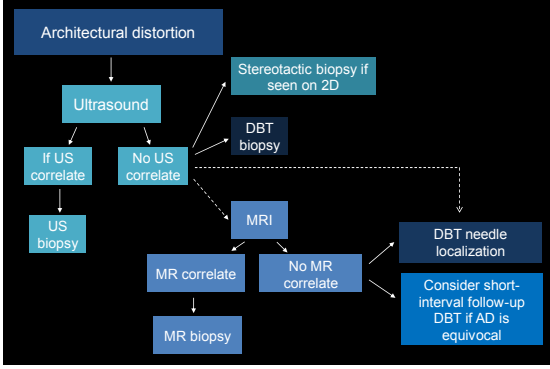

Not COPY

CESM for AD

- 49 AD with CESM prior to biopsy
  - 29 invasive cancers, 1 DCIS, 9 radial scars, 10 benign
  - 76% (37/49) AD showed enhancement
  - Sensitivity 97%, NPV 92%
  - 1 FN: 4 mm lesion within substantial BPE

Patel et al Clinical utility of contrast-enhanced spectral mammography as an adjunct for tomosynthesis-detected architectural distortion. Clin Imaging 2017;46:44-52.

62-year-old recalled from screening mammography for AD in the R UIQ. History of 2 benign R MR biopsies for NME.

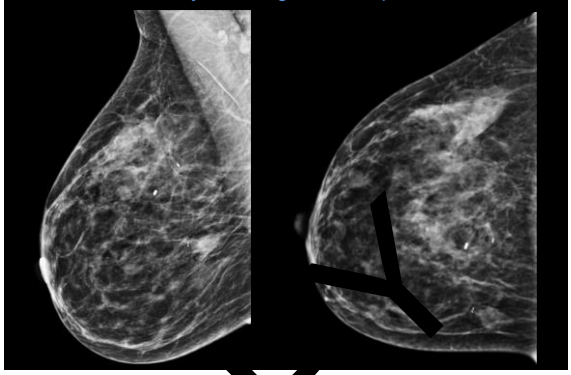

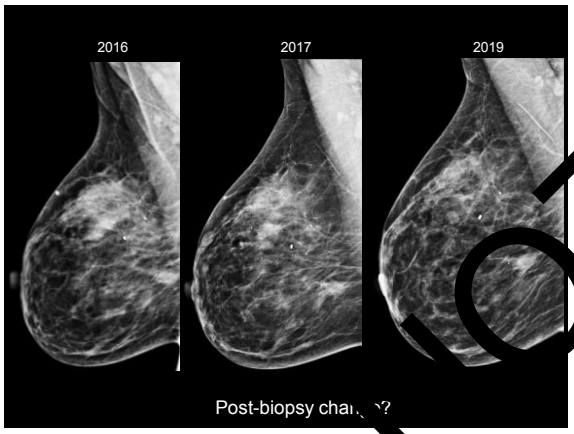

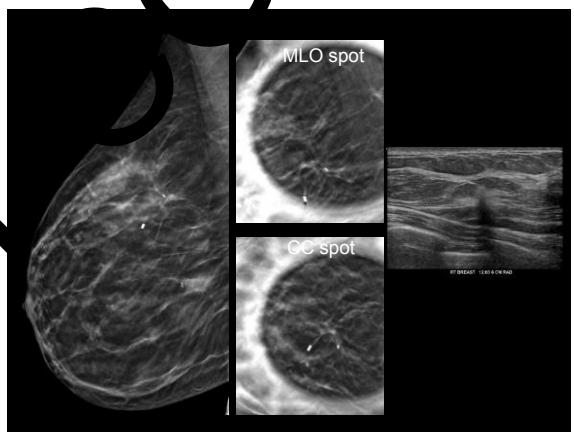

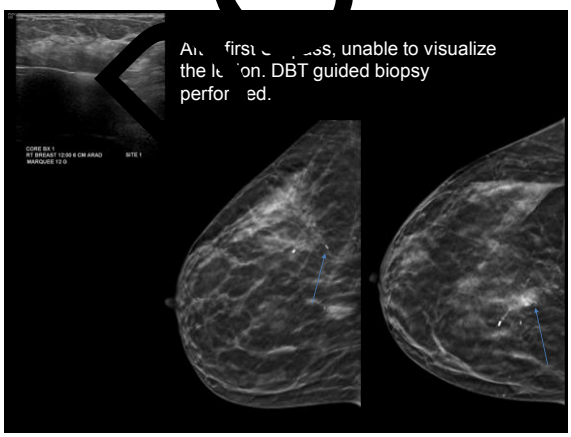

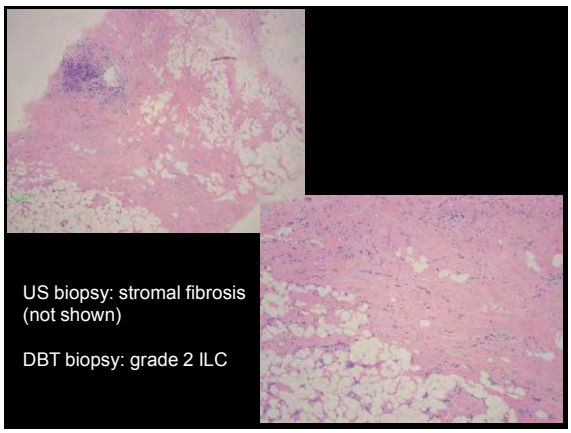

PROOF

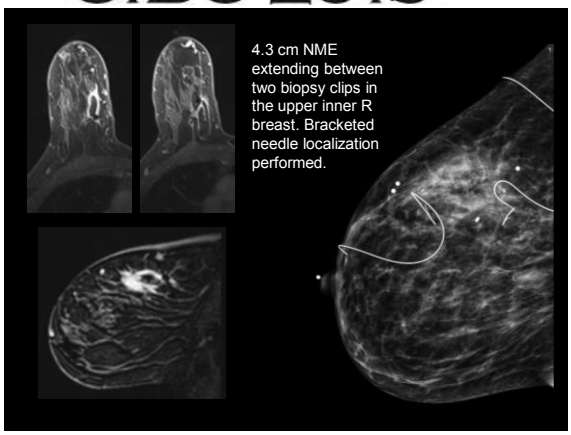

4.3 cm NME extending between two biopsy clips in the upper inner R breast. Bracketed needle localization performed.

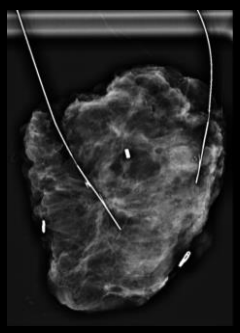

Surgical pathology: Grade 2 ILC spanning 4.2 cm, positive posterior margin and one lymph node with ıre isolated tumor cells

AD and Cancer Types

- More common in Luminal A and B tumors[1]
- Lower grade tumors[2,3]
  - 96% malignancies low or intermediate grade[2]
- Lobular histology[2,4-7]
- Most are invasive (>80%) vs DCIS
  - DCIS more common for DBT-only AD[8]

[1]Baré et al., Mammographic and clinical characteristics of different phenotypes of screen-detected and interval breast cancers in a ... screening ... Breast Cancer Res Treat. 2015.
[2]Pujara et al., Architectural distortion in the era of digital breast tomosynthesis: outcomes and implications for management. Clin Imaging.
[3]Patel et al., Initial Experience of Tomosynthesis-Guided Vacuum-Assisted Biopsies of Tomosynthesis-Detected (2D Mammography and Ult... Occult) Architectural Distortions. AJR Am J Roentgenol. 2018.
[4]Charming's P. Imaging features and conspicuity of invasive lobular carcinomas on digital breast tomosy... 2017.
[5]Bahl et al., Architectural Distortion on Mammography: Correlation With Pathologic Outcomes and Predicto...
[6]Patel et al., Clinical utility of contrast-enhanced spectral mammography as an adjunct for tomosynthesis-dete... Intecou...
[7]Ray et al., Suspicious Findings at Digital Breast Tomosynthesis Occult to Conventional Digital Mammography: ... Features and Patho... ...al J, 2015.
[8]Alshafeiy et al., Outcome of Architectural Distortion Detected Only at Breast Tomosynthesis versus 2D Mammogra... ...diology, 2018.

Can imaging features help predict malignancy?

- Greater likelihood of malignancy with 2D vs DBT
  - 43.5% vs 10.2%[1]
  - 88% vs 68%[2]
  - 73.6% vs 50.7%[3]

[1]Alshafeiy et al., Radiology, 2018.
[2]Vijapura et al., AJR 2018.
[3]Bahl et al., AJR 2017.

Can imaging features help predict malignancy?

- Greater likelihood of malignancy with US correlate
  - 39.7% vs 11.1%[1]
  - 46% vs 15%[2]
  - 82.9% vs 27.9%[3]
  - 97% vs 83%[4]
  - 66.5% vs 29.2%[5]

[1]Alshafeiy et al., Radiology, 2018.
[2]Pujara et al., Clin Imaging 2019.
[3]Bahl et al., AJR 2015.
[4]Vijapura et al., AJR 2018.
[5]Bahl et al., AJR 2017.

Can imaging features help predict malignancy?

- Trend toward increased malignancy rate for AD with Ca++ or asymmetries vs pure AD on DM[1,2]
- One-view only distortion can be malignant[3]
  - 23% (3/13) one-view AD malignant
  - 2 of 3: ILC
  - All seen on CC view only

[1]Bahl et al., AJR 2015.
[2]Bahl et al., AJR 2017.
[3]Pujara et al., Clin Imaging 2019.

PROOF

Can imaging features help predict malignancy?

- Nonmalignant AD:
  - symmetric or spoke-wheel spiculation with central lucency
- Malignant AD:
  - asymmetric spiculation and central mass
- Nonmalignant AD either better detected or detected only on DBT.

Vijapura et al. Imaging Features of Nonmalignant and Malignant Architectural Distortion Detected by Tomosynthesis. AJR 2018; Dec;211(6):1397-1404.

Challenge Cases: Multiple AD

48-year-old recalled from screening mammography.

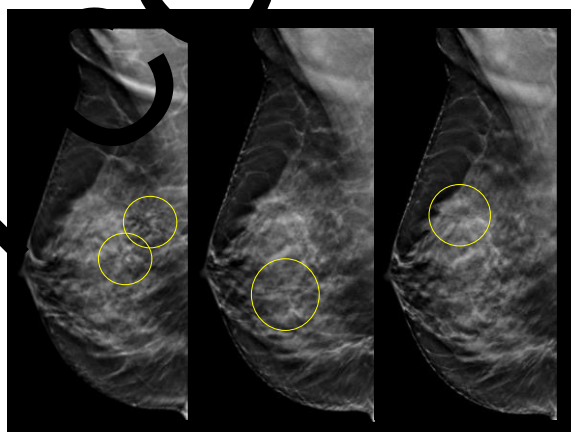

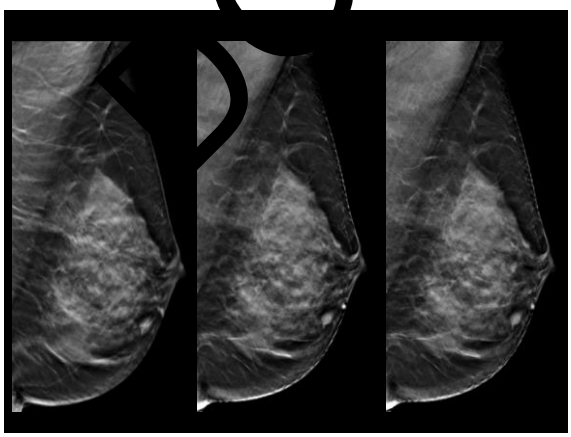

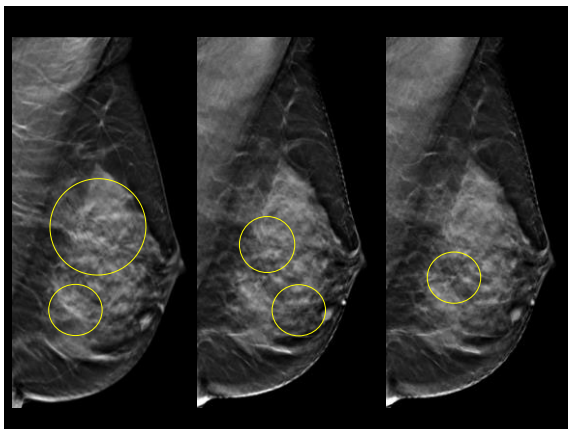

Do not cop

No definite sonographic abnormality identified to correspond to the numerous areas of architectural distortion seen on mammography.

Management?

Problem-Solving MRI

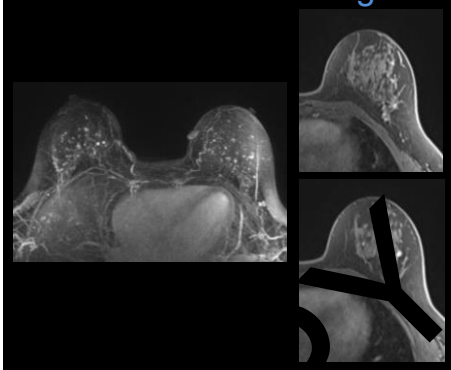

MR biopsy = Radial scar

MR biopsy = Nodular sclerosing adenosis

Radial Scar Appearance on MRI

- 29 radial sclerosing lesions[1]
  - 9 occult on MRI
  - 20 MRI: 1 focus, 10 masses, 4 NME, 5 "AD"
  - 7/9 RSL presenting as AD were visible on MR
- 18/30 AD were radial scars[2]
  - None showed enhancement on MRI

[1]Linda et al. Magnetic resonance imaging of radial sclerosing lesions (radial scars) of the breast. Eu[illegible]iol 2012 Nov;81(1[illegible]
[2]Pediconi et al. Radial Scars of the Breast: Contrast-enhanced Magnetic Resonance Mammography A[illegible]nce. Breast J. 11 (1) (2005). [illegible]. 23-28.

Surgical excision was not performed.

No interval mammographic change over 3 years.

55-year-old wit[illegible]r exc[illegible]ion of R [illegible]dial scar/FEA, recent L stereotactic [illegible]opsy o[illegible]D at [illegible]H revealing radial scar.

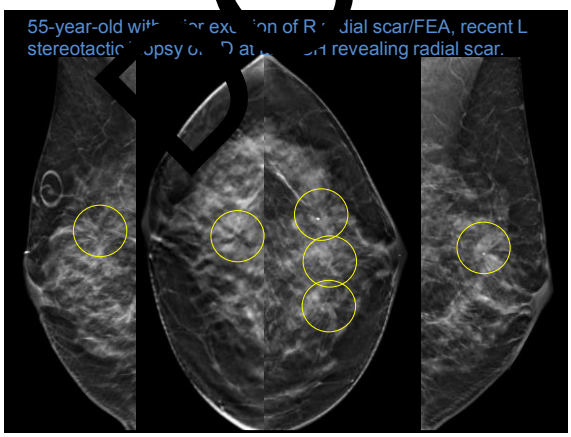

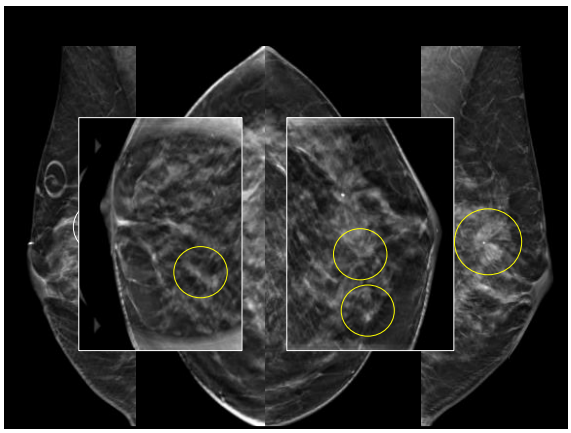

DO NOT COPY

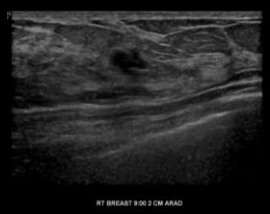

DBT biopsy AD left central inner, left central, and right upper inner breast and US biopsy hypoechoic mass right at 9:00 2 cm from the nipple recommended.

Post-biopsy mammogram

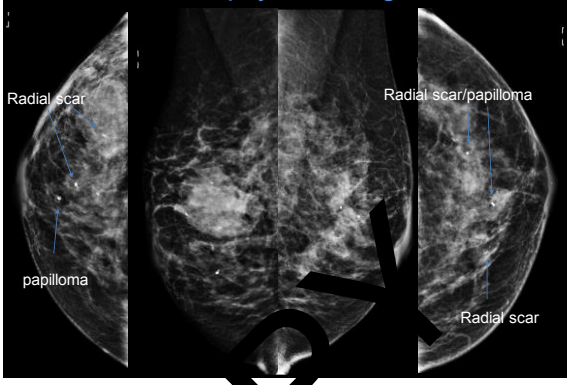

Management?

Bilateral needle localization

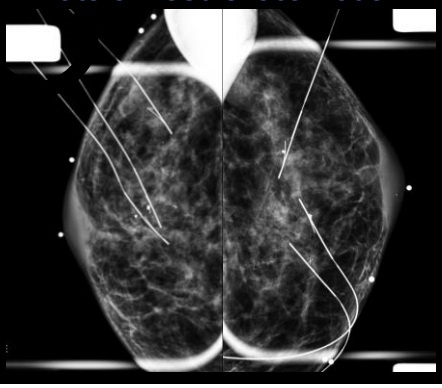

Surgical Pathology

- Left medial: multiple radial scars, multiple intraductal papillomas, sclerosing adenosis
- Left lateral: multiple radial scars, multiple intraductal papillomas with associated UDH
- Right breast lateral: multiple radial scars, multiple intraductal papillomas, sclerosing adenosis, PASH
- Right inferior: multiple radial scars, ALH, FEA, multiple papillomas, PASH

DO NOT COPY

Multiple Radial Scars

- Nurses' Health Study: 460 cases and 1792 controls with BBD
- Among women with RS
  - One RS 67.3%
  - Two RS 16.7%
  - ≥3 RS 16.0%
- Women with multiple RS at higher risk of breast cancer than women with single RS (RR 2.7 vs 1.5, p = 0.12)

Aroner et al. Radial scars and subsequent breast cancer risk: results from the Nurses' Health Studies. Breast Cancer Res Treat 2013, Volume 139, Issue 1, pp 277–285.

Bilateral Symmetric AD

62-year-old presents for annual mammography.
History of breast reduction 2004.

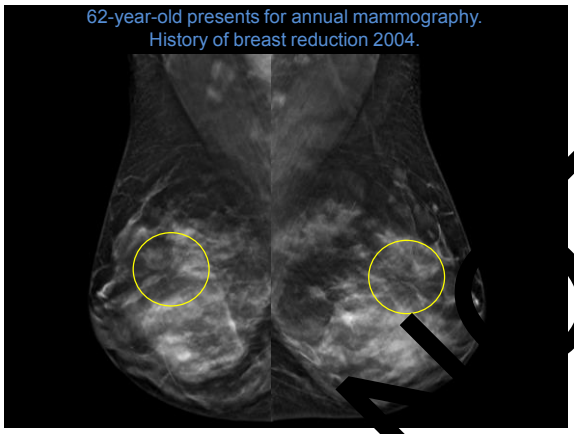

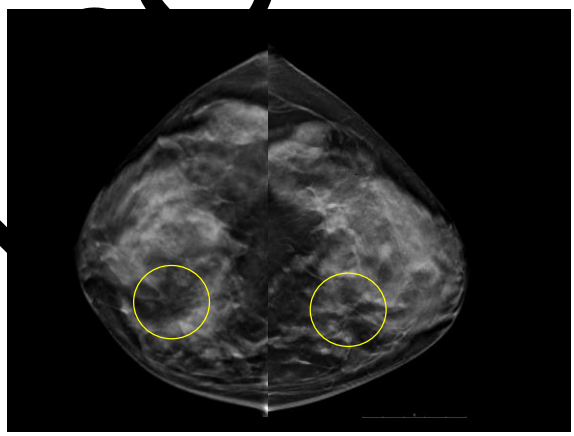

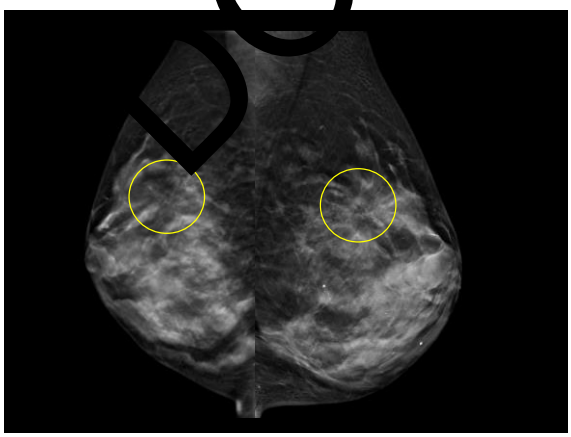

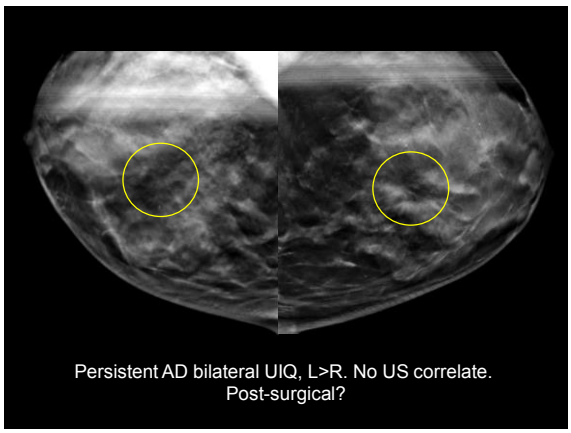

Persistent AD bilateral UIQ, L>R. No US correlate.
Post-surgical?

DO NOT COPY

Left DBT biopsy

Pathology: DCIS, grades 2 and 3 with lobular extension into a radial scar

Right DBT biopsy

Path… DCIS, grade 3 with lobu… extension and focal micro… asion.

51-year-old recalled from screening mammography.

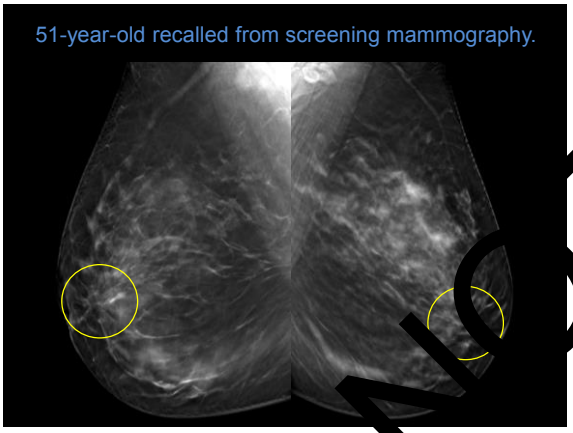

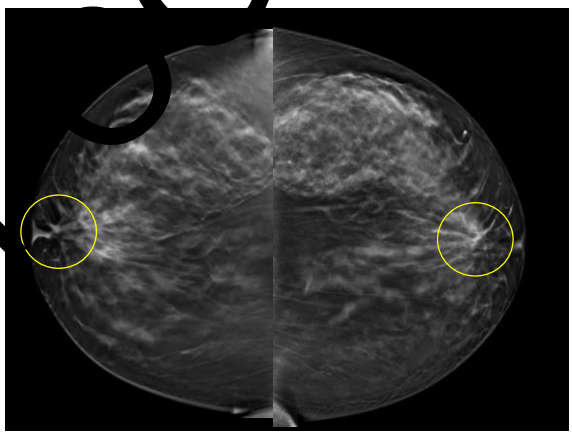

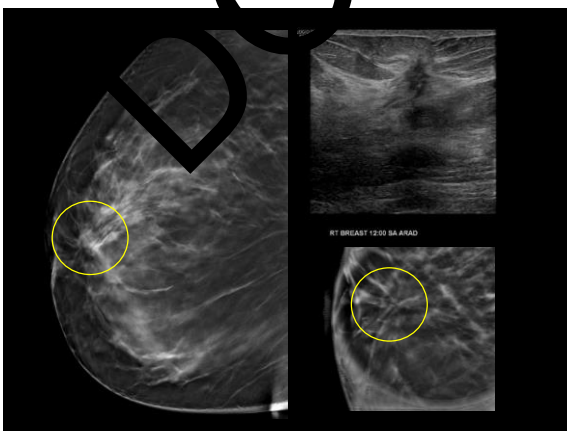

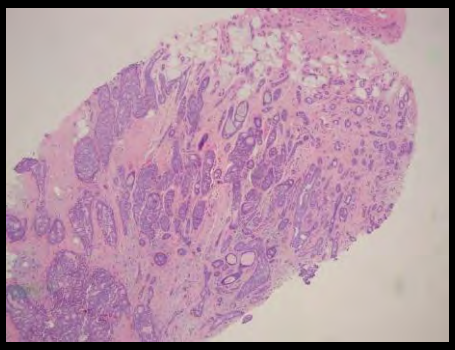

US biopsy revealed DCIS involving a complex sclerosing lesion.

DO NOT COPY

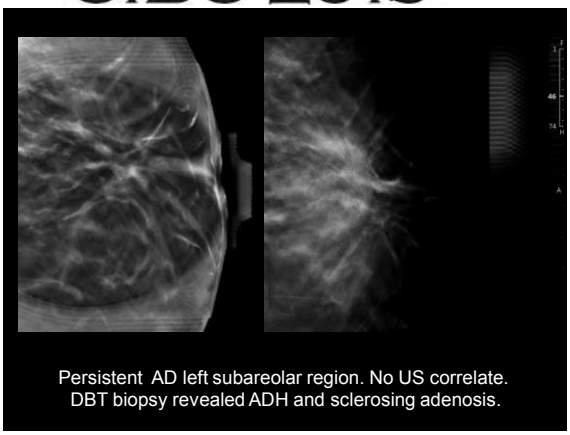

Persistent AD left subareolar region. No US correlate. DBT biopsy revealed ADH and sclerosing adenosis.

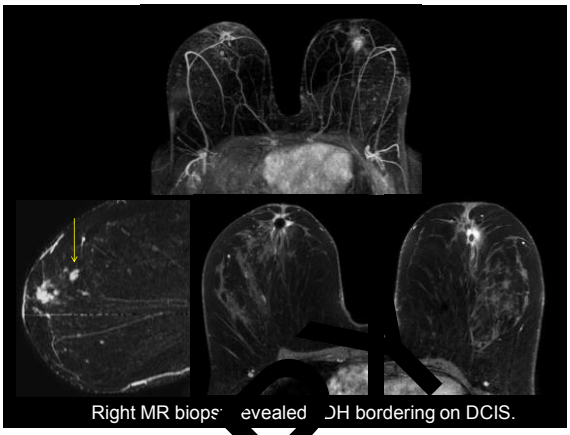

Right MR biops[illegible]evealed [illegible]DH bordering on DCIS.

Bilateral Surgical Excision

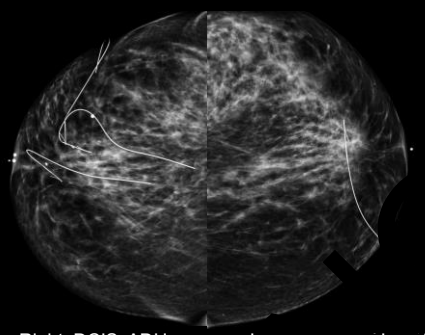

Right: DCIS, ADH Le[illegible]

Management of Biopsy Results for AD

- Malignant → excise
- High risk lesions
  - ADH → excise
  - Pleomorphic LCIS → excise
  - Radial scar → controversial
- Benign → nothing additional if adequate sampling and rad-path concordance

85-[illegible]old [illegible]alled f[illegible]m screening mamm[illegible]graphy. [illegible]tory o[illegible] bilateral lumpectomies.

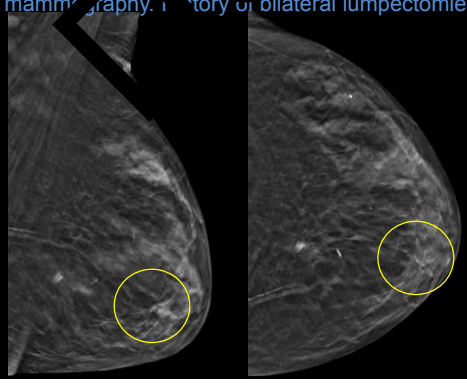

Persistent AD upper central left breast.

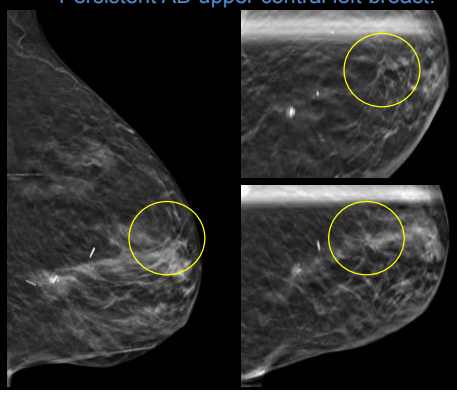

DRAFT COPY

Ultrasound Correlate

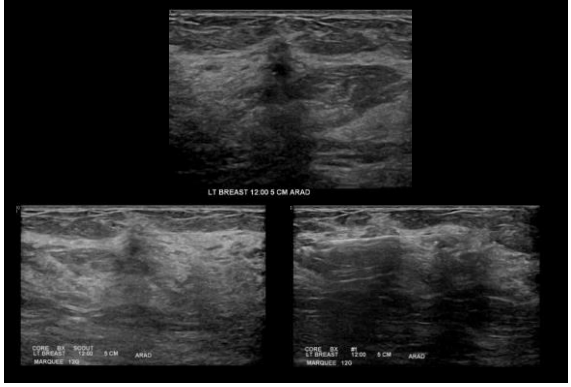

Post-biopsy clip correlation

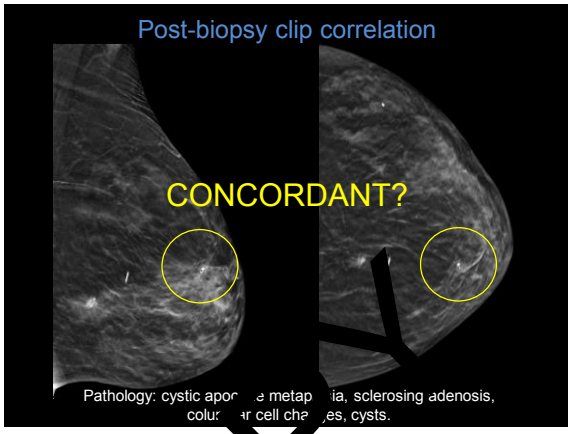

Needle localization for surgical excision

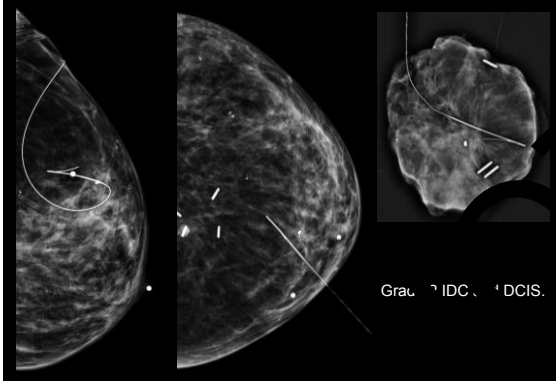

Radiology-Pathology
Concordance is Key!

Summary

- AD is the most commonly missed manifestation of cancer with high interobserver variability
- Increased detection of AD with DBT
- Higher rate of malignancy with US correlate
- DBT-only AD warrants biopsy
- Careful post-biopsy evaluation paramount:
  - Radiology-pathology concordance
  - Post-biopsy clip correlation

POST